

# SMOOTH MUSCLE TUMORS OF THE UTERUS PATHOLOGY

Jaime Prat, M.D.

The diagnosis of uterine leiomyosarcoma is usually straightforward since most clinically malignant smooth muscle tumors of the uterus show the microscopic constellation of hypercellularity, severe nuclear atypia, and high mitotic rate generally exceeding 15 mitotic figures per 10 high-power-fields (MF/10 HPF).<sup>1-3</sup> Frequently, one or more supportive clinicopathologic features such as peri- or postmenopausal age, extrauterine extension, large size (over 10 cm), infiltrating border, necrosis, and atypical mitotic figures are also present.<sup>3</sup> In contrast, the minimal pathologic criteria for a diagnosis of leiomyosarcoma are more problematic and, in such cases, the differential diagnosis has to be made, not only with a variety of benign smooth muscle tumors that exhibit atypical histologic features and unusual growth patterns, but also with *smooth muscle tumors of uncertain malignant potential* (STUMP).

The specific subtypes of leiomyoma that mimic malignancy are:

- Mitotically active leiomyoma
- Cellular leiomyoma
- Hemorrhagic leiomyoma and hormone-induced changes
- Leiomyoma with bizarre nuclei (atypical leiomyoma)
- Myxoid leiomyoma
- Epithelioid leiomyoma
- Leiomyoma with massive lymphoid infiltration

## Mitotically active leiomyoma (MAL)

In premenopausal women, otherwise typical leiomyomas may occasionally show 5 or more MF/10 HPF. These tumors have a benign clinical course (even when treated by myomectomy).<sup>4-5</sup> Mitotic rate is usually 5-9 MF/10 HPF, but occasional MAL with 10-20 MF/10 HPF have been reported. The tumors are typically small (<10 cm) and have a benign gross appearance. Tumors exhibiting severe nuclear atypia, abnormal mitoses, or tumor necrosis should not be diagnosed as MALs. Approximately 60% of MALs are submucosal leiomyomas.

## Cellular leiomyoma

Leiomyomas that are unusually cellular but otherwise typical have a clinical behavior identical to usual leiomyomas.<sup>6,7</sup> Grossly, cellular leiomyomas may resemble typical leiomyomas but often have a fleshier sectioned surface. Microscopically, cellular leiomyomas almost always have < 5MF/10 HPF and are cytologically bland. Cellular leiomyomas may resemble endometrial stromal tumors. Helpful features in the differential diagnosis are:

- Coexistence of the highly cellular areas with a fascicular growth pattern typical of smooth muscle tumors.
- Reticulin fibers that tend to parallel the fascicles of cells in leiomyomas but surround individual tumor cells in endometrial stromal tumors.
- Vessels of large caliber with thick muscular walls; in contrast to the prominent network of small blood vessels typical of endometrial stromal tumors.

- Strong and multifocal or diffuse immunoreactivity for smooth muscle markers such as desmin and h-caldesmon.

In the absence of vascular invasion, the distinction is between two benign lesions; i.e., cellular leiomyoma and endometrial stromal nodule. However, when there is intravascular tumor, the differential is clinically relevant; i.e. intravenous leiomyomatosis versus endometrial stromal sarcoma. In young women wishing to retain their fertility or in older women with high surgical risk, hysteroscopy, imaging studies or repeat sampling should be considered before hysterectomy.

## Hemorrhagic leiomyoma and hormone-induced changes

Various morphologic changes may be seen in leiomyomas from pregnant women and those on progestin therapy. These include hemorrhage, edema, myxoid change, focal hypercellularity, nuclear pleomorphism, and increased mitotic activity.<sup>8</sup> Patients may present with acute abdominal signs secondary to rupture of the tumor into the peritoneal cavity. Microscopic examination reveals densely cellular proliferations of smooth muscle cells surrounding geographic zones of recent hemorrhage. Although the tumor cells lack malignant nuclear features, as many as 8 MF/10HPF have been encountered in some cases.<sup>8</sup> Leiomyomas treated with gonadotropin-releasing hormone agonists (GnRHa) to reduce their size prior to their removal, may exhibit the features of apoplectic leiomyomas, and vascular changes (i.e., myxoid change, fibrinoid change, mural thickening, luminal narrowing, and thrombosis). Leiomyomas removed several weeks after withdrawal of GnRHa treatment may have increased mitotic activity.

## Leiomyoma with bizarre nuclei (atypical leiomyoma)

As an isolated finding, nuclear atypia, even when severe, is an insufficient criterion for the diagnosis of leiomyosarcoma. Occasionally, leiomyomas may contain cells with bizarrely shaped, multilobated or multinucleated, hyperchromatic nuclei. The atypical cells may be distributed throughout the leiomyoma or, more frequently, in discrete perivascular foci. These tumors are variously referred to as "atypical", "symplastic", or "bizarre" leiomyomas.<sup>1,2,9</sup>

- *Grossly*, these tumors may resemble conventional leiomyomas or may show yellow to tan areas, hemorrhage, or myxoid change.
- *Microscopically*, the defining feature is the presence of bizarre pleomorphic cells with abundant eosinophilic cytoplasm, prominent nuclear pseudoinclusions, and atypical nuclei distributed throughout the tumor or in discrete foci. Typically, the areas uninvolved by the bizarre cells show bland cytologic features. Although most of the atypical cells are multinucleated, mononucleated are also seen. The nuclei are often pyknotic with dense smudged chromatin. A worrisome feature in some tumors is a high mitotic count, up to 7MF/10 HPF by the highest count method.<sup>9</sup> By the average method, however, it ranges from 0 to 2.8 MF/10 HPF (mean 0.8). Confusion with leiomyosarcoma can be enhanced when degenerating or karyorrhectic nuclei are mistaken for atypical mitotic figures.<sup>9</sup>

Leiomyomas with bizarre nuclei are distinguished from leiomyosarcomas by an absence of tumor cell necrosis and mitotic counts of < 10MF/10 HPFs. A mitotic index higher than 10 MF/10 HPF in an atypical smooth muscle tumor is diagnostic of malignancy. Combination of aneuploidy and high MIB-1 activity is rare in bizarre leiomyomas and, in such cases, the diagnosis should be made with caution.<sup>10</sup> Several studies have shown that leiomyomas with bizarre nuclei have a benign clinical course.<sup>1,2,9</sup> However, otherwise typical leiomyosarcomas may contain areas indistinguishable from atypical

leiomyomas. In such cases, the finding of atypical mitotic figures and tumor cell necrosis helps in establishing the correct diagnosis.

## Myxoid leiomyomas

Myxoid leiomyomas may occur during pregnancy. Grossly, they resemble extrauterine myxomas. Microscopically, they show well-defined borders and contain abundant, acellular, pale-staining material rich in acid mucins which stain with alcian blue or colloidal iron. The neoplastic cells may be elongated or stellate in shape and are widely separated by the extracellular material. Cytologic features are bland and mitotic figures are rare. In curettage specimens, distinction between myxoid leiomyoma and myxoid leiomyosarcoma may be difficult. Non-myxoid portions of the leiomyoma may be erroneously interpreted as evidence of myometrial invasion. In a recent study,<sup>11</sup> a mitotic index of <2 MFs /10 HPFs in the absence of tumor cell necrosis or severe cytologic atypia favored the diagnosis of myxoid leiomyoma. However, large myxoid smooth muscle tumors and those with an infiltrating margin, moderate to severe nuclear atypia, with or without necrosis and any mitotic index, should be regarded myxoid leiomyosarcomas.

## Epithelioid leiomyomas

Epithelioid leiomyomas are composed of polygonal cells containing abundant eosinophilic cytoplasm. These tumors are also known as *clear cell leiomyomas* or *leiomyoblastomas*.<sup>12</sup> Grossly, they may resemble typical leiomyomas or appear fleshy due to their high cellularity. The average diameter is 6-7 cm. *Microscopically*, epithelioid leiomyomas often exhibit a diffuse growth pattern, but nests, cords, or pseudoglandular spaces are usually found. The cell cytoplasm is characteristically eosinophilic and granular, but it may be clear (*clear cell leiomyoma*). The round or angular nuclei are typically central but may be eccentric, occasionally resulting in a signet-ring appearance. Immunohistochemically, these tumors are more frequently positive for cytokeratins and less often positive for smooth muscle markers than nonepithelioid smooth muscle tumors.<sup>13,14</sup>

Because of the rarity of epithelioid smooth muscle tumors, criteria predictive of their malignant behavior are less well established than that for spindle-cell smooth muscle tumors. In an old study of 26 cases, small size, expansile margin, presence of clear cytoplasm, extensive hyalinization, and lack of extensive necrosis are parameters associated with a favorable prognosis; whereas larger tumors (>6 cm) that exhibit 5 or more MFs/10 HPFs should be designated as epithelioid leiomyosarcomas.<sup>12</sup> In a more recent study,<sup>13</sup> there was not a single histologic feature predictive of outcome. Clinically malignant tumors showed grade 3 nuclei, mitotic activity >3/10 HPFs, and tumor cell necrosis. An unpublished study<sup>14</sup> of 32 epithelioid smooth muscle tumors, found that, in the absence of tumor cell necrosis, either moderate to severe nuclear atypia or a mitotic index of 5 or more MFs/10 HPFs warrants a diagnosis of malignancy. Tumors with moderate to severe atypia, without necrosis, and MI < 5/10 HPF should be classified as STUMP.<sup>14</sup>

The differential diagnosis of epithelioid smooth muscle tumors includes primary endometrial or metastatic carcinoma (especially those composed of eosinophilic or clear cells), placental site trophoblastic tumor (PSTT) or epithelioid trophoblastic tumor (ETT), and low-grade endometrial stromal sarcoma. Desmin immunoreactivity, absence of the characteristic features of PSTT and ETT, and lack of the vascular-space invasion typically seen in low-grade endometrial stromal sarcoma facilitate the correct diagnosis.

Recently, a low-grade mesenchymal tumor of the soft tissues and uterus thought to derive from perivascular epithelioid cells has been described as **PEComa**.<sup>15</sup> The tumor cells are arranged in sheets or solid nests, contain oval to round nuclei, exhibit abundant clear or eosinophilic cytoplasm,

and often express smooth muscle markers. PEComas typically immunoreact for HMB-45 and other melanocytic markers such as Melan A.<sup>15,16</sup> Some tumors may be associated with lymphangi leiomyomatosis and the tuberous sclerosis syndrome. As experience with these tumors is very limited, their long-term prognosis is unknown. Some cases have behaved aggressively.<sup>15,16</sup>

Rarely, leiomyomas may contain a massive lymphoid infiltrate that may be confused with lymphoma or inflammatory pseudotumor, which rarely may involve the uterus.

## Smooth muscle tumors with unusual growth patterns

The designation **leiomyoma with vascular invasion** refers to an otherwise typical leiomyoma with microscopic intravascular growth confined to the tumor.<sup>1</sup> Although most of these tumors are clinically benign, several cases have been associated with benign smooth muscle nodules in the lungs (*benign metastasizing leiomyoma*, see below) while other cases may represent an early stage of intravenous leiomyomatosis.

Leiomyoma with vascular invasion should be distinguished from **intravenous leiomyomatosis**, a very rare tumor characterized by nodular masses of benign-appearing smooth muscle cells growing within veins beyond the confines or in the absence of a leiomyoma.<sup>17-19</sup> Extrauterine extension into the pelvic veins and vena cava has been reported in 80% and over 10% of patients, respectively. In some cases, the tumor has reached the right side of the heart, sometimes with fatal consequences.<sup>18,20</sup> The median age of patients with intravenous leiomyomatosis is 45 years.

Grossly, the myometrium contains multiple nodules with wormlike extensions into the uterine veins in the broad ligament. On section, the masses vary from soft to rubbery and firm, and appear pink-white or gray. On histologic examination, the intravascular growth usually resembles a typical leiomyoma, but occasionally it is reminiscent of one or another variant of leiomyoma.<sup>21</sup> The intravenous tumor has often a clefted or lobulated contour, and its appearance may be altered by extensive hydropic change or hyalinization, and numerous thick-walled vessels. Arteries are not involved. Mitotic figures are usually rare, but cellular intravenous leiomyomatosis may contain up to 4 MFs/10 HPFs. In contrast to low-grade endometrial stromal sarcoma, cellular intravenous leiomyomatosis typically shows thick-walled blood vessels in its intravascular extension. Intravenous leiomyomatosis is a hormonally dependent tumor.<sup>17,18</sup> GnRH-agonists may be useful in controlling unresectable tumor.

*Diffuse leiomyomatosis* is a rare lesion characterized by symmetrical uterine enlargement due to innumerable small smooth muscle nodules.<sup>22</sup> The uterus may be weighing up to 1000 g. The nodules range from microscopic to 3 cm in size. Microscopically, they are composed of uniform, cytologically bland, mitotically-inactive, spindled smooth muscle cells and are less circumscribed than typical leiomyomas. Differential diagnosis includes rare cases of uterine involvement by lymphangi leiomyomatosis, usually in patients with tuberous sclerosis (autosomal dominant disorder; facial angiofibromas, retinal hamartomas, and renal angiomyolipomas). The smooth muscle cells of lymphangi leiomyomatosis are immunoreactive for HMB-45.

*Benign metastasizing leiomyoma* is a rare disorder characterized by 'metastatic' nodules of benign-appearing smooth muscle in the lung, lymph nodes, or abdomen of women, most of whom have a history of uterine leiomyomas removed previously.<sup>23,24</sup> Typically, the primary tumor has been resected many years prior to the development of extrauterine disease. Often, the primary tumor has been inadequately studied and mitotic counts are not recorded. Some cases may represent deportation metastases from intravenous leiomyomatosis. Others may result from smooth muscle proliferation involving the uterus and extrauterine sites. A recent cytogenetic study has favored the monoclonal origin of both uterine and pulmonary tumors and interpreted the pulmonary tumors as metastatic.

*Disseminated peritoneal leiomyomatosis (DPL)* is a rare condition characterized by widespread nodules of benign smooth muscle on the peritoneal surfaces in women of reproductive age. Most patients have uterine leiomyomas at the time of diagnosis. DPL is frequently associated with pregnancy, functioning granulosa cell tumors, or oral contraceptives. The most common presentation is as an incidental finding at the time of cesarean section. The intraoperative appearance of DPL is so alarming that frozen section examination is often requested to rule out peritoneal carcinomatosis. The nodules are usually small (<1 cm in diameter), firm, grayish-white, and cover the peritoneal surface of the uterus, adnexa, intestines, and omentum; this differs from metastatic leiomyosarcoma, in which the nodules tend to be fewer, larger, and invasive into adjacent tissues. Microscopically, the nodules of DPL consist of smooth muscle cells, fibroblasts, myofibroblasts, and, in pregnancy or the postpartum, decidual cells. Nuclear pleomorphism and hypercellularity are absent. Mitotic figures are inconspicuous. Lymph node involvement may occur. DPL expresses desmin, smooth muscle actin, CD10, and ER and PR. The etiology of DPL is unknown. A metaplastic transformation of the subperitoneal mesenchyme has been proposed. DPL may regress after therapy with GnRH agonist. Five cases of malignant DPL have been reported and recently reviewed.

## **Leiomyosarcomas**

After excluding carcinosarcomas, which are now classified as a dedifferentiated or metaplastic form of endometrial carcinoma, leiomyosarcomas are thought to represent the most common form of uterine sarcoma. However, they only account for 1-2% of uterine malignancies. Most occur in women over 40 years of age who frequently present abnormal vaginal bleeding, pain or both. Occasionally, the presenting manifestations are related to tumor rupture (hemoperitoneum), extrauterine extension (one-third to one-half of cases), or metastases. Only very rarely, a leiomyosarcoma originates from a leiomyoma.

### **Macroscopic features**

Typically large solitary masses with a mean diameter of 10 cm. Approximately 25% of the tumors are < 5 cm in size. About two-thirds of leiomyosarcomas are intramural, 1/5 submucosal, and 1/10 subserosal; 5% arise in the cervix. They are almost always less circumscribed than leiomyomas. The cut surface is typically bulging, fleshy, focally necrotic, and hemorrhagic. When a myometrial tumor shows an unusual gross appearance, thorough sampling is recommended (at least one section per cm in diameter). Leiomyosarcomas are either a single mass or -when associated with leiomyomas- the largest mass.

### **Microscopic features**

On microscopic examination, most uterine leiomyosarcomas are obviously malignant and, besides destructive myometrial invasion, show:

- At least, moderate hypercellularity.
- Moderate to marked nuclear atypia, usually diffuse.
- High mitotic rate (10 or more MFs /10 HPFs; over 90% have > 15 MFs/10 HPFs).
- Tumor necrosis (geographic necrosis), characterized by an abrupt transition from the viable cells to the necrotic cells without an interposed zone of granulation tissue or fibrous tissue. Preserved nuclei with marked pleomorphism and hyperchromasia can still be seen within the necrotic areas and often there is a perivascular growth of viable tumor cells. Tumor necrosis is highly characteristic of leiomyosarcomas.

Tumor necrosis should be distinguished from **infarct-type necrosis** (which may be seen in benign or malignant smooth muscle tumors) and is characterized by a transition zone composed of granulation or fibrous (hyalinized) tissue depending upon the age of the infarct. The necrotic tissue has a mummified and homogeneous appearance, areas of hemorrhage are common, and no perivascular growth of tumor cells is seen. According to Bell et al.<sup>25</sup> the presence of 2 of the 3 criteria (nuclear atypia, high mitotic rate, and tumor cell necrosis) warrants a diagnosis of leiomyosarcoma. In some cases, distinguishing between tumor necrosis and infarct-type necrosis may be difficult.

Leiomyosarcomas are aggressive tumors.<sup>26-28</sup> In a large Gynecology Oncology Group (GOG) study,<sup>29</sup> the recurrent rate was 71%. First recurrences were in the lungs in 40% of patients, and in the pelvis in only 13%. Survival rate ranged from 15% to 25%, with a median survival of only 10 months in one study. There has been no consistency among various studies regarding correlation between survival and patient age, clinical stage, tumor size, type of border (pushing versus infiltrative), presence or absence of necrosis, mitotic rate, degree of nuclear pleomorphism, and vascular invasion.<sup>30,31</sup> One study, however, found tumor size to be a major prognostic parameter: five of 8 patients with tumors < 5 cm in diameter survived, whereas all patients with tumors > 5 cm in diameter died of tumor. In this study of 208 uterine leiomyosarcomas, the only parameters predictive of prognosis were tumor grade and stage.<sup>27</sup> Tumor grade, however, has not been consistently identified as a significant prognostic parameter. Possibly, many of the so-called "low-grade" leiomyosarcomas may in fact represent histologic variants of leiomyomas frequently misdiagnosed as sarcomas (such as cellular, mitotically active, epithelioid, myxoid, and atypical leiomyomas).

Rare malignant smooth muscle tumors lacking the high mitotic activity of typical leiomyosarcomas include epithelioid and myxoid leiomyosarcomas.

*Epithelioid leiomyosarcomas* are composed predominantly or entirely of round or polygonal cells exhibiting eosinophilic or clear cytoplasm.<sup>12-14</sup> Tumor cells grow diffusely in nests, cords, or forming a plexiform pattern. Although nuclear pleomorphism is usually mild, some tumors show moderate to marked nuclear atypia. Mitotic rate is generally <3 MFs/10 HPFs. Most tumors infiltrate the adjacent myometrium but vascular invasion is rare. Necrosis may be absent. Three of 26 tumors in one series recurred or metastasized.<sup>12</sup> The malignant tumors exhibited one or more of the following features: eosinophilic cells, infiltrating margin, necrosis, diameter greater than 6 cm, and absence of hyaline stroma.<sup>12</sup>

*Myxoid leiomyosarcomas* are grossly gelatinous (>50%) and microscopically show a sparsely cellular, myxoid appearance.<sup>32</sup> In contrast to conventional leiomyosarcomas, most tumors are hypocellular. Myxoid leiomyosarcomas are almost always clinically malignant despite low mitotic rates (0-2 MFs/10 HPFs) (40%)<sup>11</sup> and bland nuclear features; in the absence of severe cytologic atypia and tumor cell necrosis, they are diagnosed as sarcomas based on their infiltrative borders. They show abundant basophilic or eosinophilic myxoid matrix that reacts strongly with alcian blue and colloidal iron. Smooth muscle markers are detected immunohistochemically in <25% of tumor cells.

Recently, several immunohistochemical and molecular genetic studies on uterine leiomyosarcomas have been reported.<sup>33-38</sup> Although leiomyosarcomas usually express smooth muscle markers such as desmin, h-caldesmon, smooth muscle actin, and HDCA8. Epithelioid and myxoid leiomyosarcomas may show lesser degrees of immunoreaction for these markers. Conventional leiomyosarcomas express ER, PR, and AR in 30-40% of cases. Also, immunoreaction for CD117 (but no *c-kit* mutations) has been found. Several studies have shown that uterine leiomyosarcomas have a significantly higher Ki67 index than benign smooth muscle tumors.<sup>34,37</sup> Mutation and overexpression of p53 have been described in uterine leiomyosarcomas.<sup>34,37,38</sup> It has been reported that 32% and 83% of leiomyosarcomas showed

p53 immunoreaction in >50% and >25% of the tumor cells, respectively. In contrast, only 4% of the atypical leiomyomas exhibited a positive p53 immunoreaction

Overexpression of p16 has recently been described in uterine leiomyosarcomas and found to be higher than in leiomyomas.<sup>35-37</sup> In the former tumors, its reported frequency ranged from 57% to 100% and immunoreaction was found in from >25% to >50% of tumor cells. Contrariwise, 13% or less of uterine leiomyomas showed p16 immunoreaction. In one study, however, up to 60% of atypical (bizarre) leiomyomas showed immunostaining for p16.<sup>37</sup> Another study revealed a correlation between p16 overexpression and poor outcome.<sup>35</sup>

## Smooth muscle tumors of uncertain malignant potential (STUMP)

Combining the results of 8 series in the literature, Zaloudek and Norris,<sup>1</sup> found that 75% of cellular smooth muscle tumors with mitotic rates of 5 or more MFs/10HPFs were clinically malignant (i.e. leiomyosarcoma), whereas those with 4 or fewer MFs/10HPFs were almost invariably benign; all of the clinically malignant tumors were cytologically atypical. Therefore, the criteria proposed by these authors for leiomyosarcoma were the simultaneous presence of 5 or more MFs/10HPFs and cytologic atypia.

Uterine smooth muscle tumors that are unclassifiable by current criteria as unequivocally benign or malignant have been referred to as **smooth muscle tumors of uncertain malignant potential (STUMP)** although as yet there is no uniform definition of these tumors. Criteria used by Bell et al.<sup>25</sup> include moderate to severe cytologic atypia and <10 MFs/10 HPFs in absence of tumor necrosis. In contrast, O'Connor and Norris<sup>4</sup> render a diagnosis of STUMP when there are 5-9 MFs/10 HPFs and mild (grade 1/3) nuclear atypia.

STUMPs were subdivided in the study by Bell et al.<sup>25</sup> into three groups:

- a) *Atypical leiomyoma with low risk of recurrence*, showing diffuse moderate to severe atypia, <10 MFs/ 10 HPFs, and no tumor cell necrosis. Only one of 46 such tumors was clinically malignant.
- b) *Atypical leiomyoma but limited experience*, was characterized by focal moderate to severe atypia, <20 MFs/ 10 HPFs, and no tumor cell necrosis. There were only five cases in this group and all were clinically benign. Three of the five tumors had <5 MFs/ 10 HPFs and would be considered leiomyomas with bizarre nuclei by most investigators. The other two tumors had 10-19 MFs/10 HPFs.
- c) *Smooth muscle tumors of low malignant potential*, had tumor cell necrosis, <10 MFs/ 10 HPFs, and absent to mild atypia. One of four tumors in this group was clinically malignant, again underscoring the importance of tumor cell necrosis.

Currently, it is believed that leiomyosarcomas are associated with poor prognosis even when confined to the uterus (stage I). Conversely, most tumors classified as STUMP have been associated with favorable prognosis and, in these cases, only follow-up of the patient is recommended.

## REFERENCES

1. Zaloudek CJ, Norris HJ. Mesenchymal tumors of the uterus. In: Progress in Surgical Pathology. Vol. III. Fenoglio CM and Wolff M, eds. New York: Masson-Publishing Inc., 1981:1-35.
2. Evans HL, Chawla SP, Simpson C, Finn KP. Smooth muscle tumors of the uterus other than ordinary leiomyoma. A study of 46 cases, with emphasis on diagnostic criteria and prognostic factors. *Cancer* 1988; 62:2239-2247.
3. Perrone T, Dehner LP. Prognostically favorable "mitotically active" smooth-muscle tumors of the uterus. A clinicopathologic study of 10 cases. *Am J Surg Pathol* 1988; 12:1-8.
4. O'Connor DM, Norris HJ. Mitotically active leiomyomas of the uterus. *Hum Pathol* 1990; 21:223-227.
5. Prayson RA, Hart WR. Mitotically active leiomyomas of the uterus. *Am J Clin Pathol* 1992; 97:14-20.
6. Oliva E, Clement PB, Young RY. Mesenchymal tumors of the uterus: selected topics emphasizing diagnostic pitfalls. *Current Diag Pathol* 2002; 8:268-282.
7. Oliva E, Young RH, Clement PB, Bhan AK, Scully RE. Cellular benign mesenchymal tumors of the uterus. A comparative morphologic and immunohistochemical analysis of 33 highly cellular leiomyomas and six endometrial stromal nodules, two frequently confused tumors. *Am J Surg Pathol* 1995; 19:757-768.
8. Myles JL, Hart WR. Apoplectic leiomyomas of the uterus. A clinicopathologic study of five distinctive hemorrhagic leiomyomas associated with oral contraceptive usage. *Am J Surg Pathol* 1985; 9:798-805.
9. Downes KA, Hart WR. Bizarre leiomyomas of the uterus: A comprehensive pathologic study of 24 cases with long term follow-up. *Am J Surg Pathol* 1997; 21:1261-70.
10. Downes KA, Hart WR. Bizarre uterine leiomyomas: Ki-67 activity and DNA ploidy. Abstract. *Mod Pathol* 1999; 12:116A.
11. Atkins K, Bell S, Kempson M, Hendrickson M. Myxoid smooth muscle tumors of the uterus. *Modern Pathol* 2001; 14:132A.
12. Kurman RJ, Norris HJ. Mesenchymal tumors of the uterus. VI. Epithelioid smooth muscle tumors including leiomyoblastoma and clear-cell leiomyoma. A clinical and pathological analysis of 26 cases. *Cancer* 1976; 37:1853-1865.
13. Prayson RA, Goldblum JR, Hart WR. Epithelioid smooth-muscle tumors of the uterus: A clinicopathologic study of 18 patients. *Am J Surg Pathol* 1997; 21:383-91.
14. Atkins K, Bell S, Kempson R, Hendrickson M. Epithelioid smooth muscle of the uterus. *Modern Pathol* 2001; 14:132A.
15. Vang R, Kempson RL. Perivascular epithelioid cell tumor (PEComa) of the uterus: A subset of HMB-45-positive epithelioid mesenchymal neoplasms with an uncertain relationship to pure smooth muscle tumors. *Am J Surg Pathol* 2002; 26:1-13.

16. Folpe A, Mentzel T, Lehr HA, Fisher C, Balzer BL, Weiss SW. Perivascular epithelioid cell neoplasms of soft tissue and gynecologic origin: a clinicopathologic study of 26 cases and review of the literature. *Am J Surg Pathol* 2005; 29:1558-1575.
17. Norris HJ, Parmley T. Mesenchymal tumors of the uterus. V. Intravenous leiomyomatosis. A clinical and pathologic study of 14 cases. *Cancer* 1975; 36:2164-2178.
18. Clement PB. Intravenous leiomyomatosis. *Pathol Annu* 1988; 23:153-183.
19. Mulvany NJ, Slavin JL, Ostor AG, Fortune DW. Intravenous leiomyomatosis of the uterus: a clinicopathologic study of 22 cases. *Int J Gynecol Pathol* 1994; 13:1-9.
20. Suginami H, Kaura R, Ochi H, Matsuura S. Intravenous leiomyomatosis with cardiac extension: successful surgical management and histopathologic study. *Obstet Gynecol* 1990; 76: 527-529.
21. Clement PB, Young RH, Scully RE. Intravenous leiomyomatosis of the uterus: a clinicopathologic analysis of 16 cases with unusual histologic features. *Am J Surg Pathol* 1988; 12: 932-945.
22. Clement PB, Young RH. Diffuse leiomyomatosis of the uterus: A report of four cases. *Int J Gynecol Pathol* 1987; 6:322-328.
23. Goyle KK, Moore DF, Jr., Garret C, et al. Benign metastasizing leiomyomatosis: case report and review. *Am J Clin Oncol* 2003; 26: 473-476.
24. Rivera JA, Christopoulos S, Small D, et al. Hormonal manipulation of benign metastasizing leiomyomas: report of two cases and review of the literature. *J Clin Endocrinol Metab* 2004; 89: 3183-3188.
25. Bell SW, Kempson RL, Hendrickson MR. Problematic uterine smooth muscle neoplasms. A clinicopathologic study of 213 cases. *Am J Surg Pathol* 1994; 18:535-558.
26. Bodner K, Bodner-Adler B, Kimberger O, Czerwenka K, Leodolter S, Mayerhofer K. Evaluating prognostic parameters in women with uterine leiomyosarcoma. A clinicopathologic study. *J Reprod Med* 2003; 48:95-100.
27. Giuntoli RL, Metzinger DS, DiMarco CS, Cha SS, Sloan JA, Henney GL, Gostout BS. Retrospective review of 208 patients with leiomyosarcoma of the uterus: prognostic indicators, surgical management, and adjuvant therapy. *Gynecol Oncol* 2003; 89:460-469.
28. Leiato MM, Sonoda Y, Brennan MF, Barakat RR, Chi DS. Incidence of lymph node metastases in leiomyosarcoma of the uterus. *Gynecol Oncol* 2003; 91:209-212.
29. Major FJ, Blessing JA, Silverberg SG, et al. Prognostic factors in early-stage uterine sarcoma. A Gynecologic Oncology Group study. *Cancer* 1993; 71:1702-1709.
30. Kapp DS, Shin JY, Chan JK. Prognostic factors and survival in 1396 patients with uterine leiomyosarcomas: emphasis on impact of lymphadenectomy and oophorectomy. *Cancer* 2008; 112:820-830.

31. Koivisto-Korander R, Butzow R, Koivisto AM, Leminen A. Clinical outcome and prognostic factors in 100 cases of uterine sarcoma: experience in Helsinki University Central Hospital 1990-2001. *Gynecol Oncol.* 2008; 111:74-81.
32. King ME, Dickersin GR, Scully RE. Myxoid leiomyosarcoma of the uterus. A report of six cases. *Am J Surg Pathol* 1982; 6:589-598.
33. Rao UN, Finkelstein SD, Jones MW. Comparative immunohistochemical and molecular analysis of uterine and extrauterine leiomyosarcomas. *Mod Pathol* 1999;12:1001-1009.
34. Akhan SE, Yavuz E, Tecer A et al. The expression of Ki-67, p53, estrogen and progesterone receptors affecting survival in uterine leiomyosarcomas. A clinicopathologic study. *Gynecol Oncol.* 2005; 99:36-42.
35. Atkins KA, Arronte N, Darus CJ, Rice LW. The Use of p16 in enhancing the histologic classification of uterine smooth muscle tumors. *Am J Surg Pathol.* 2008; 32:98-102.
36. Bodner-Adler B, Bodner K, Czerwenka K, Kimberger O, Leodolter S, Mayerhofer K. Expression of p16 protein in patients with uterine smooth muscle tumors: an immunohistochemical analysis. *Gynecol Oncol.* 2005; 96:62-66.
37. Chen L, Yang B. Immunohistochemical analysis of p16, p53, and Ki-67 expression in uterine smooth muscle tumors. *Int J Gynecol Pathol.* 2008; 27:326-332.
38. Jeffers MD, Farquharson MA, Richmond JA, McNicol AM. P53 immunoreactivity and mutation of the p53 gene in smooth muscle tumours of the uterine corpus. *J Pathol* 1995; 177:65-70.

# Smooth Muscle Tumors of the Uterus

## Pathology

Jaime Prat, M.D.

Hospital de la Santa Creu i Sant Pau  
Autonomous University of Barcelona, Spain

# Smooth Muscle Tumors of the Uterus (Outline)

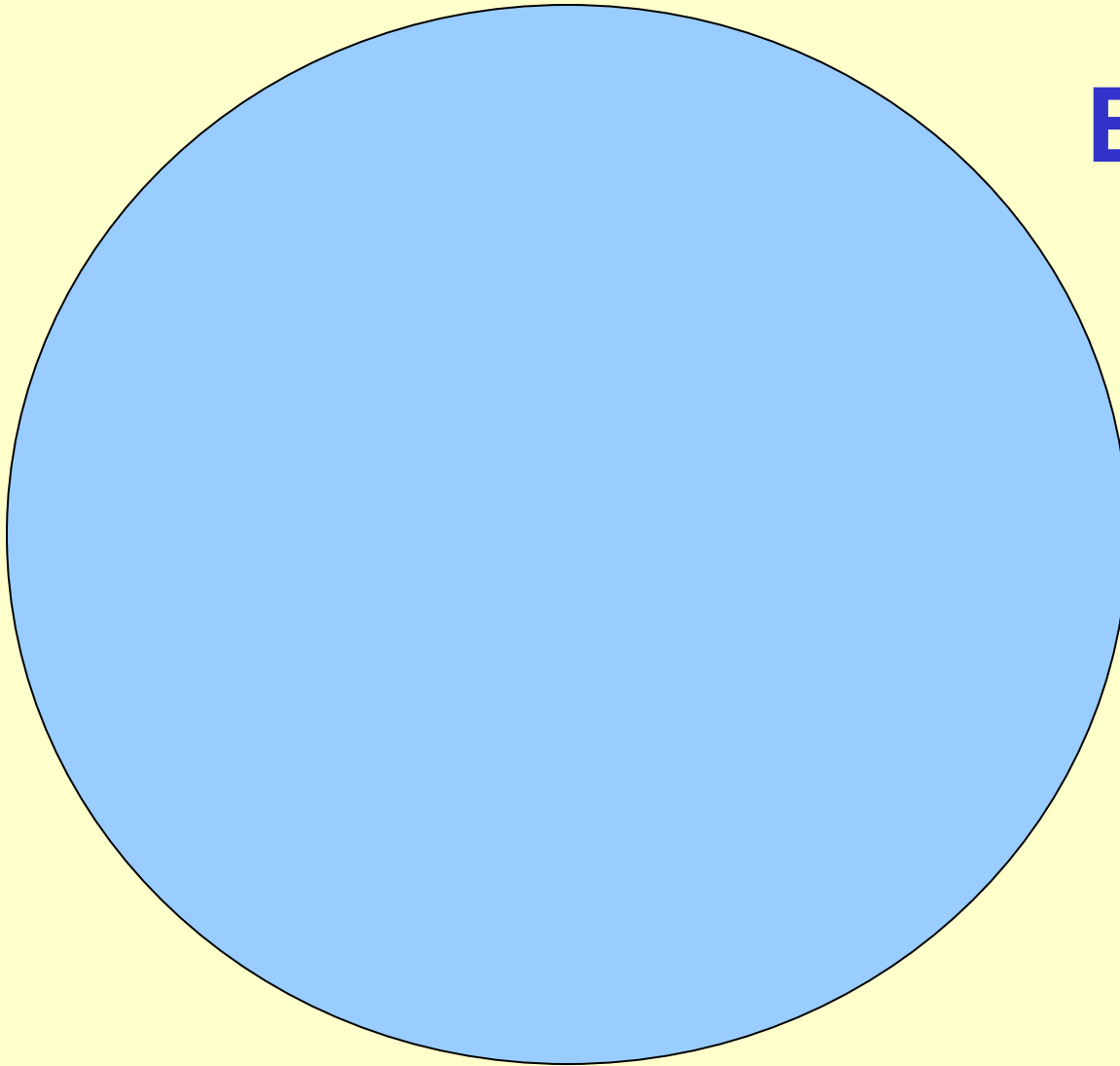
- Typical leiomyosarcoma
- Rare variants (Epithelioid & Myxoid)
- Leiomyoma variants (WHO 2003)
- Prognostic factors (lack of...)
- Staging
- Minimal pathologic criteria
- Uncertain malignant potential

# Uterine Sarcomas

(3% of Uterine Cancers)

- Leiomyosarcomas 30%
- Mx Mixed Mesodermal Tumors 50%  
(Carcinosarcomas)
- Endometrial Stromal Sarcomas 15%
- Undifferentiated Sarcomas 5%

# Smooth Muscle Tumors of the Uterus



**Benign**

Clinically Malignant



Malignant or atypical  
for the pathologist



# Leiomyosarcoma

- Dx is usually straightforward
- Over 90% of cases:
  - Hypercellularity
  - Marked nuclear atypia
  - High mitotic rate (15 MF/10 HPF)

# Leiomyosarcoma

(Additional relevant findings)

- Peri- or postmenopausal age
- Extrauterine extension
- Diameter over 10 cm
- Infiltrating border
- Coagulative necrosis
- Atypical mitoses

Perrone T. Dehner LP  
Am J Surg Pathol 1988; 12:1-8

# Leiomyosarcoma

(Rare variants)

- Epithelioid LMS
- Myxoid LMS

# Epithelioid Leiomyosarcoma

- Diameter > 6 cm
- Infiltrative margin
- 3-5 mitoses/10 HPF
- Necrosis +/-

# Myxoid Leiomyosarcoma

- Gelatinous/myxoid (>50%)
- Infiltrative borders
- Bland nuclear features
- 0-2 mitoses/10 HPF (40%)
- Smooth muscle markers  
(<25% of tumor cells)
- CD10 + / ALK-1 -
- Poor prognosis

# Leiomyosarcomas

- Most uterine sarcomas are leiomyosarcomas
- The vast majority of leiomyosarcomas are high-grade sarcomas associated with poor prognosis
- 259 patients from Norway: 51% 5 yr survival (IGCS 2008)
- Application of 2003 WHO criteria
- Possibly, many of the so-called “low-grade” leiomyosarcomas may in fact represent histologic variants of leiomyomas frequently misdiagnosed as sarcomas

# Leiomyoma-variants

- Mitotically active leiomyoma (MAL)
- Cellular leiomyoma
- Epithelioid leiomyoma
- Leiomyoma with bizarre nuclei
- Leiomyoma with vascular invasion
- Intravenous leiomyomatosis
- Benign metastasizing leiomyoma
- Diffuse leiomyomatosis

# **Mitotically Active Leiomyoma** **(Up to 15 Mit/10HPF)**

- Small (< 10 cm)
- Grossly benign
- Submucosal
- No nuclear atypia
- Young women
- Secretory phase
- Pregnancy/Progestins

# Cellular Leiomyoma

- Fascicular growth pattern
- Thick-walled vessels
- Positive desmin/h-caldesmon
- Misdiagnosed as stromal tumor

Oliva E et al.  
Am J Surg Pathol 1995

# Epithelioid Leiomyoma

- Nests, cords, pseudoglands
- Eosinophilic or clear cells
- No necrosis/No atypia
- Hyalinization
- < 5 mitoses/10 HPF
- Positive CK
- Diff Dx: Carcinoma

Prayson RA et al.  
Am J Surg Pathol 1997

# Bizarre Leiomyoma (24 cases with Follow-up)

Age: 25 - 51 (av 40) yr

Size: 1 - 14 (av 4.2) cm

8% >10 cm

Color: yellow-tan (33%)

Border: sharp (50%)

Cell: 1+ (21%), 2+ (58%), 3+ (21%)

Giant cells: focal (12.5%)

multif (37.5%)

diff (50%)

Tumor necrosis: 0/24

Downes & Hart

Am J Surg Pathol 1997; 21:1261

# Bizarre Leiomyoma (24 cases with Follow-up)

Mitosis: Average 0-2.8/10 HPF (m 0.8)

Highest 0-7/10 HPF (m 1.6)

Hysterectomy: 20/24

Myomectomy: 6/24 (+2 Hysterectomy)

Follow-up: 1.0-18.9 (m 11.2) yr

All alive and well

Downes & Hart  
Am J Surg Pathol 1997

# Bizarre Leiomyoma versus Leiomyosarcoma

	BL	LMS
Mitotic count	< 10	> 10
Tumor cell necrosis	-	+
DNA ploidy	Diploid	Aneuploid
MIB-1	Low	High
p53	-	+

Downes KA and Hart WR, 1999

**A note of caution:**

**Leiomyosarcomas may  
show superimposed  
“bizarre” change!**

# Intravenous Leiomyomatosis

- Extrauterine extension 80%
- Leiomyoma or variants
- Thick-walled vessels
- Up to 4 mitoses/10 HPF

Leiomyosarcomas are high-grade sarcomas associated with poor prognosis even if at Stage I

# Uterine Leiomyosarcomas (5 yr Surv)

Stage I	40-70%
Overall	15-25%

# Staging of Uterine Leiomyosarcomas

<b>Stage</b>	<b>Definition</b>
I	Tumor limited to uterus
IA	< 5 cm
IB	> 5 cm
II	Tumor extends to the pelvis
IIA	Adnexal involvement
IIB	Tumor extends to extrauterine pelvic tissue
III	Tumor invades abdominal tissues (not just protruding into abdomen)
IIIA	One site
IIB	> one site
IIIC	Metastasis to pelvic and/or para-aortic lymph nodes
IV	Tumor invades bladder and/or rectum and/or distant metastasis
IVA	Tumor invades bladder and/or rectum
IVB	Distant metastasis

FIGO Committee on Gynecol Oncol  
Staging for uterine sarcomas  
Int J Gynecol Obstet 2009

# Leiomyosarcomas

## (Inconsistent Prognostics Factors)

- Age
- Stage
- Size
- Border (pushing vs infiltrative)
- Necrosis
- Mitosis
- Nuclear atypia
- Vascular invasion

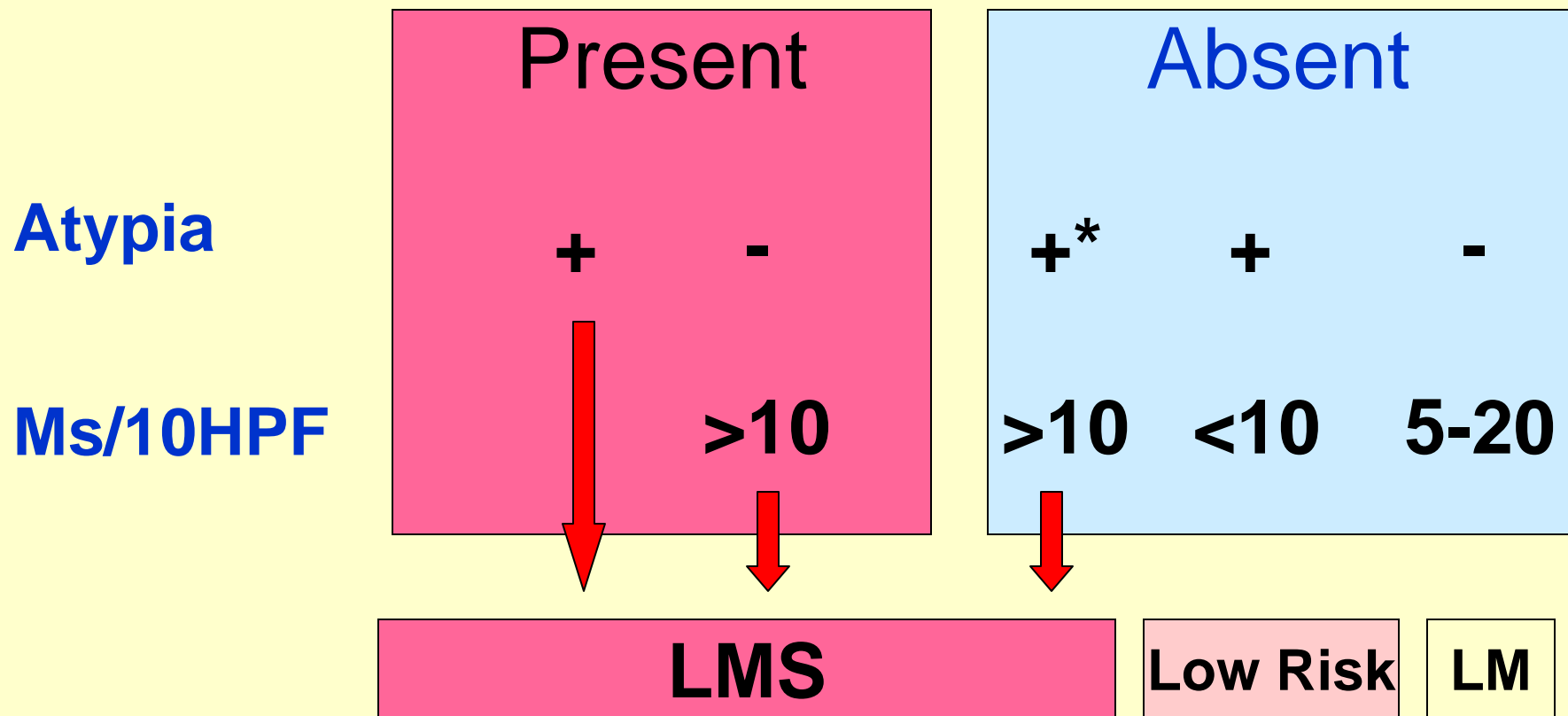
# Cellular & Atypical Smooth Muscle Tumors of the Uterus

5+ Mit/10HPF Malignant (75%)  
4- Mit/10HPF Benign

Zaloudek & Norris, 1981

# Uterine Smooth Muscle Tumors

## Tumor Necrosis



Bell SW et al., 1994

\* diffuse or focal

# Smooth Muscle Tumors of Uncertain Malignant Potential "STUMPS"

- Tumor cell necrosis in a typical leiomyoma
- Necrosis of uncertain type with 10 or more MFs/10 HPFs, or marked diffuse atypia
- Marked diffuse atypia with borderline mitotic counts
- Marked focal atypia and 10 or more MFs/10 HPFs

# Leiomyosarcomas

(Immunohistochemistry)

- Proliferation markers (Ki-67, p53, p16, Twist) are usually overexpressed
- A subset of LMS lacking proliferation markers and expressing bcl-2 may be associated with good prognosis

D'Angelo E, et al., 2009

# Smooth Muscle Tumors of the Uterus (Summary)

- Leiomyosarcomas are high-grade tumors
- Leiomyoma variants (overdiagnosis)
- Leiomyosarcomas may show “bizarre” change
- Minimal diagnostic criteria: mitoses are necessary but insufficient (size, atypia, necrosis)
- Epithelioid and Myxoid tumors (watch out!)
- Uncertain malignant potential (follow-up)