

# RENAL NONAMYLOIDOTIC MONOCLONAL IMMUNOGLOBULIN DEPOSITION DISEASES: UPDATE 2009

Guillermo A. Herrera MD

**KEY WORDS:** Light / heavy chain deposition disease / plasma cell dyscrasia / immunofluorescence / electron microscopy / immunoelectron microscopy

## Historical perspective:

Since the late 1950s it was suspected that nodular glomerulosclerosis was not a unique lesion in diabetic nephropathy and that this lesion may also be found in patients with myeloma. However, definitive proof was lacking until the 1970s.

Antonovych et al in 1976 were the first to recognize the association of monotypical light chains with punctate electron dense deposits in glomeruli.

In 1978 Randall et al. published a seminal manuscript with autopsy findings in two patients and coined the term light chain deposition disease. Randall and associates capitalized on the information available to them from the examination of multiple organs to recognize a new entity with primary clinical and pathologic manifestations centered on the kidneys, but with systemic involvement. It is interesting that Randall et al concluded in the abstract of this manuscript: "The deposition (of monoclonal kappa light chains) in these patients may be an extreme example of a common but previously unrecognized form of plasma cell dyscrasia". The authors indicate in the same paper that "such deposition has not been reported previously" which was not a completely accurate statement.

Another important contribution of this seminal publication was the establishment of a conceptual link between circulating abnormal light chains, deposition of these in various organs, and the development of

disease as a direct consequence. That these abnormal light chains because of their peculiar structural alterations were directly responsible for their deposition in various organs was also emphasized in the publication. This concept, revolutionary at the time, has proven to be correct.

Currently our understanding of these disorders has advanced considerably with contributions from basic research providing crucial insights into the pathogenesis of light chain deposition disease.

Heavy chain deposition disease was not described until 1993 by Aucouturier et al. The similarities between this condition and light chain deposition disease were noted from the very beginning. Unfortunately, our understanding of the pathogenesis of heavy chain deposition diseases is not as detailed at the present time.

## **NOMENCLATURE**

Currently we recognize light and heavy chain deposition diseases (L/HCDDs) and combinations of these with other manifestations of plasma cell dyscrasias in the kidney. In terms of clinical and pathologic manifestations, light, heavy and combined light/heavy deposition diseases are similar; therefore, some prefer to use the designation of MONOCLONAL IMMUNOGLOBULIN DEPOSITION DISEASE to encompass all of these. Examples of combinations include light and heavy chain deposition disease, light chain cast nephropathy and light chain deposition disease, light chain deposition disease and proximal tubulopathy with intracytoplasmic proximal tubular inclusions, as seen in Fanconi syndrome, and light chain deposition disease combined with AL-amyloidosis have been described.

## **CLINICAL MANIFESTATIONS**

Renal manifestations are very common in these disorders and similar in light and heavy chain deposition diseases. Proteinuria and renal insufficiency are the most common manifestations. Hypertension is also present in a significant number of these patients. These diseases have been documented in transplanted kidneys, either as a de-novo process or recurrence. Approximately one quarter of these patients have manifestations in other organs, most commonly liver, heart and lungs. Involvement of other organs, including brain and skin, and peripheral

nerves has also been documented in the literature. Because the clinical presentation are so varied and rather non specific, when this diagnosis is made is usually a surprise to the clinicians.

## **RENAL MANIFESTATIONS**

Because of the similarities between light and heavy chain deposition diseases, their renal manifestations will be described together.

All renal compartments can be affected and the immunomorphologic manifestations can be quite varied. For purposes of conveying a clearer message, the manifestations in the various compartments will be described separately, although they are generally manifested in more than one compartment. It is quite unusual for only one compartment to be affected, although such can happen rarely.

### **IMMUNOFUORESCENCE: Light and heavy chains generally involved in these diseases:**

Kappa light chains are most common in light chain deposition disease (approximately 85% of patients with LCDD). Kappa 1 and 4 are the subtypes most often involved. Generally linear (or interrupted linear) staining is noted in areas where light chain deposits are present. Glomerular deposits are generally less intense than those along tubular basement membranes, but not always.

Gamma heavy chains are most common in heavy chain deposition disease. However alpha and mu chains can also be involved. In most cases of HCDD, especially when gamma 1 or 3 chains are involved, complement components, including C1 can be demonstrated exhibiting granular or pseudolinear patterns. Decreased serum complement is also commonly present in these situations. Stains for kappa and lambda light chains are negative in heavy chain deposition disease.

Immunofluoresce antibodies to light and heavy chains detect the majority of these cases, but not all. In some instances, the light and heavy chains are so abnormal that the commercially available antibodies cannot detect them in tissue deposits. It is important not to rule out these conditions if the immunofluorescence is negative. Ultrastructural labeling can depict monoclonal light and heavy chains in many instances in

which the immunofluorescence is negative or inconclusive, attesting to its increased sensitivity.

Antibodies to constant domains of the heavy chain molecule, mainly to the CH1 (most cases) but also CH2 and hinge regions confirm the diagnosis by demonstrating their deletion in cases of heavy chain deposition disease.

## **LIGHT MICROSCOPY AND PATHOGENESIS**

### **Glomerular findings:**

The classical and best described glomerular manifestation is that of a nodular glomerulopathy- nodular glomerulosclerosis with features that mimic diabetic nephropathy. This is; however, the advanced stage of both light and heavy chain deposition diseases. In the very early stages, the glomeruli may appear essentially unremarkable by light microscopy (so-called minimal change glomerulopathy). In these cases, the monotypical light chains are identified in subendothelial spaces and closely interacting with the glomerular basement membranes which leads to loss of the filtration barrier. Nephrotic range at times non selective proteinuria, containing albumin and/or other proteins (not only light chains) is typical of this stage. Once light chains (and presumably) heavy chains interact with mesangial cells, using a purported receptor for glomerulopathic light chains, secretion and activation of PDGF-B, a proliferative factor, occurs resulting in an increase in mesangial cells, creating a mesangial proliferative pattern. A progressive increase in PDGF-B secretion by the mesangial cells leads to more pronounced glomerular cellular proliferation and a membranoproliferative pattern ensues. Even crescents are found in some cases, more commonly in heavy than in light chain deposition disease. Then, TGF-beta is produced by the mesangial cells. Once TGF-B becomes activated, matrix deposition begins, and when the effects of this growth factor prevails over that of PDGF-B, inhibition of cellular proliferation takes place and matrix deposition is enhanced, eventually leading to the nodular glomerulopathy (nodular glomerulosclerosis) identified in the renal biopsies. Depending at what stage the disease process is caught when the renal biopsy is performed, the glomerular morphology may be any of the above described patterns. Thus, a high degree of suspicion with careful correlation with immunofluorescence and ultrastructural findings is

needed to make the correct diagnosis, when unusual morphologic patterns are present.

Tenascin is the protein deposited in the expanded mesangial areas in light chain deposition disease. Tenascin is a difficult to catabolize, tenacious extracellular matrix protein. Metalloproteinase 7 (MMP-7) is the main metalloproteinase involved in the catabolism of tenascin. There is a defect in secretion of metalloproteinase 7 (MMP-7) from the mesangial cells which facilitates progressive accumulation of tenascin in the mesangial nodules. An in-vitro model of light chain deposition disease has dissected the entire process of mesangial nodule formation with emphasis on molecular events. The discovery of the sequential events leading to mesangial nodule formation and how glomerulopathic light chains interact with mesangial cells to produce mesangial alterations in light chain deposition disease provides a platform that allows design of new therapeutic modalities to completely inhibit, delay, or ameliorate the pathologic processes that lead to end stage renal damage.

### **Tubular interstitial findings**

Deposition of monoclonal light chains along tubular basement membranes is the most characteristic finding. This is represented by a peculiar thickening of the tubular basement membranes which is highlighted on the PAS stain. This material is ribbon-like, refractile, and is located along the outer aspect of the tubular basement membranes, most commonly along distal tubules, but may be found around collecting ducts in the medulla as well. This; however, is only seen when the amount of deposited light chains reaches a certain point. In some cases the tubular changes are the predominant finding and in selected cases, the typical linear fluorescence is only seen along tubular basement membranes and not in glomeruli or any other renal locations.

The deposition of light chains in the interstitium elicits an inflammatory reaction. The inflammation is composed of mononuclear inflammatory cells but eosinophils may also be seen and tubulitis, often focal, is invariably noted. It may mimic an acute tubular interstitial nephritis, hypersensitivity type. Evidence of tubular damage accompanies the inflammatory interstitial process.

### **Vascular findings**

A hyperplastic vasculopathy is often present. Deposition of monoclonal light chains along the vessel walls is seen in a significant number of the cases. These findings correlate with the presence of hypertension, which at times is very difficult to control.

### **ELECTRON MICROSCOPY**

The deposits in these conditions as seen ultrastructurally can show variable appearance (both in light and heavy chain deposition diseases). The classical deposits of monotypical light or heavy chains are electron dense with a punctate to powdery appearance. However in some cases their electron density is subtle and they may even arrange in a way that they resemble electron dense deposits of the immune complex type. In some cases the deposits are not (or barely) identifiable ultrastructurally but can be depicted using immunoelectron microscopy. These light chains can be found in any of the renal compartments. In glomeruli, they are typically seen in subendothelial and mesangial locations, but can be identified on subepithelial locations, as well as on top of the glomerular basement membranes mimicking dense deposit disease. They can also be seen in Bowman's capsule, along tubular basement membranes, in the interstitium proper, and within vessel walls.

### **ULTRASTRUCTURAL IMMUNOLABELING**

This powerful technique allows exquisitely sensitive depiction of monotypical light and heavy chains in tissue. The use of immunogold labeling permits localization of pathogenic light and heavy chains to specific morphologic correlates in the various renal compartments, providing solid evidence to support an association between pathologic findings and an underlying plasma cell dyscrasia.

### **CONCLUSIONS**

Our understanding of light and heavy chain deposition diseases has increased considerably in the last 10 years. Not only our ability to diagnose the renal manifestations of these conditions has improved considerably, but the molecular mechanisms involved in their pathogenesis have been elucidated. The next step is to use this information to devise new therapeutic interventions to improve the

somewhat dismal prognosis that is currently associated with these conditions.

1. Antonovych TT, Lin RC, Parrish E. Light chain deposits in multiple myeloma. 7<sup>th</sup> Annual Meeting of the American Society of Nephrology, 1973 (Abstract 3). *Lab. Invest* 1974; 30:370A.
2. Bhargava P, Rushin JM, Rusnock EJ, et al. Pulmonary light chain deposition disease: report of five cases and review of the literature. *Am J Surg Pathol* 2007; 31: 267-276.
3. Buxbaum JN, Chuba JV, Hellman GC, Solomon A, Gallo GR. Monoclonal immunoglobulin deposition disease: light chain and light and heavy chain deposition diseases and their relation to light chain amyloidosis. Clinical features, immunopathology, and molecular analysis. *Ann Intern Med* 1990; 112:455-464.
4. Colombat M, Mal H, Copie-Bergman C, et al. Primary cystic lung light chain deposition disease: a clinicopathologic entity derived from unmutated B cells with a stereotyped IGHV4-34/IGKV1 receptor. *Blood* 2008; 112: 2004-2012.
5. Confalonieri R, Barbiano di Belgiojoso G, et al. Light chain nephropathy: Histological and clinical aspects in 15 cases. *Nephrol Dial Transplant* 1988; 3:150-156.
6. Denoroy L, Deret S, Aucouturier P: Overexpression of the V kappa IV subgroup in light chain deposition disease. *Immunol Lett* 1994; 42: 63-66.
7. Gallo GR, Feiner HD, Katz LA, et al. Nodular glomerulopathy associated with nonamyloidotic kappa light chain deposits and excess immunoglobulin light chain synthesis. *Am J Pathol* 1980; 99:621-644.
8. Ganeval D, Noël LH, Preud'homme JL, Droz D, Grünfeld JP. Light-chain deposition disease: its relation with AL-type amyloidosis. *Kidney Int* 1984; 26:1-9.
9. Gu X, Herrera GA. Light chain-mediated acute tubular interstitial nephritis: A poorly recognized pattern of renal disease in patients with plasma cell dyscrasias. *Arch Pathol Lab Med* 2006; 130:165-169.
10. Herrera GA, Russell, WJ, Isaac J et al. Glomerulopathic light chain-mesangial cell interactions modulate in vitro extracellular matrix remodeling and reproduce mesangiopathic effects documented in vivo. *Ultrastruct Pathol* 1999; 23:107-126.

11. Herrera GA, Sanders PW, Reddy BV et al: Ultrastructural immunolabeling: A unique diagnostic tool in monoclonal light chain related renal diseases. *Ultrastruct Pathol* 1994; 18: 401-416.
12. Herrera GA: Renal lesions associated with plasma cell dyscrasias: Practical approach to diagnosis, new concepts, and challenges. *Arch Pathol Lab Med* 2009 (In press).
13. Herrera GA: The contributions of electron microscopy to the understanding and diagnosis of plasma cell dyscrasia-associated renal lesions. *Med Elect Mic* 2001; 34: 1-18.
14. Hill GS, Morel-Maroger L, Méry JP, Brouet JC, Mignon F. Renal lesions in multiple myeloma: their relationship to associated protein abnormalities. *Am J Kidney Dis* 1983; 2:423-438.
15. Kambham N, Markowitz GS, Appel GB et al. Heavy chain deposition disease: The disease spectrum. *Am J Kidney Dis* 1999; 33:954-962.
16. Kaplan B, Ramirez-Alvarado M, Dispenzieri A, et al. Isolation and biochemical characterization of plasma monoclonal free light chains in amyloidosis and multiple myeloma: a pilot study of intact and truncated forms of light chains and their charge properties. *Clin Chem Lab Med* 2008; 46:335-341.
17. Keeling J, Herrera GA. Matrix metalloproteinases and mesangial remodeling in light chain-related glomerular damage. *Kidney Int* 2005; 68:1590-1603.
18. Keeling J, Herrera GA: An in vitro model of light chain deposition disease. *Kidney Int* 2009 (In press)
19. Keeling J, Teng, J, Herrera, GA. AL-amyloidosis and light chain deposition disease induce divergent phenotypic transformations of human mesangial cells. *Lab Invest* 2004; 84: 1322-1338.
20. Knobler H, Kopolovic J, Kleinman Y, et al. Multiple myeloma presenting as dense deposit disease. Light chain nephropathy. *Nephron* 1983; 34:58-63.
21. Lin J, Markowitz GS, Valeri AM et al. Renal monoclonal immunoglobulin deposition disease: The disease spectrum. *J Am Soc Nephrol* 1999; 12:1482-1492.
22. Noel LH, Droz D, Ganeval D, Grunfeld JP. Renal granular monoclonal light chain deposits: morphological aspects in 11 cases. *Clin Nephrol* 1984; 21:263-269.

23. Picken MM, Frangione B, Barlogie B, Luna M, Gallo G: Light chain deposition disease derived from the kappa light chain subgroup: Biochemical characterization. *Am J Pathol* 1989; 134: 749-754.
24. Pirani CL, Silva F, D'Agati V, Chander P, Striker LM. Renal lesions in plasma cell dyscrasias: ultrastructural observations. *Am J Kidney Dis* 1987;10: 208-221.
25. Popovic M, Tavcar R, Glavac D, Volavsek M, Pirtosek Z, Vizjak A. Light chain deposition disease restricted to the brain: The first case report. *Hum Pathol* 2007; 38:179-184.
26. Pozzi C, D'Amico M, Fogazzi GB, et al. Light chain deposition disease with renal involvement: clinical characteristics and prognostic factors. *Am J Kidney Dis* 2003; 42:1154-1163.
27. Randall RE, Williamson WC Jr, Mullinax F, Tung MY, Still WJ. Manifestations of systemic light chain deposition. *Am J Med* 1976; 60:293-299.
28. Ronco P, Plaisier E, Mougnot B, Aucouturier P. Immunoglobulin light (heavy)-chain deposition disease: from molecular medicine to pathophysiology-driven therapy. *Clin J Am Soc Nephrol* 2006; 1:1342-1350.
29. Rongioletti F, Patterson JW, Rebora A. The histological and pathogenetic spectrum of cutaneous disease in monoclonal gammopathies. *J Cutan Pathol* 2008; 35: 705-721..
30. Russell WJ, Cardelli J, Harris E et al. Monoclonal light chains-mesangial cell interactions: Early events and subsequent pathologic effects. *Lab Invest* 2001; 81:689-703.
31. Sanders PW, Herrera GA, Kirk KA et al: The spectrum of glomerular and tubularinterstitial lesions associated with monotypical immunoglobulin light chain deposition. *Lab Invest* 1991; 64:527-537.
32. Seymour AE, Thompson AJ, Smith PS, Woodroffe AJ, Clarkson AR. Kappa light chain glomerulosclerosis in multiple myeloma. *Am J Pathol* 1980; 101:557-580.
33. Sikkink LA, Ramirez-Alvarado M. Biochemical and aggregation analysis of Bence Jones proteins from different light chain diseases. *Amyloid* 2008; 15:29-39.
34. Tanenbaum ND, Howell DN, Middleton JP, Spurney RF. Lambda light chain deposition disease in a renal allograft. *Transplant Proc* 2005; 37:4289-4292.

35. Teng J, Russell WJ, Gu X et al. Different types of glomerulopathic light chains interact with mesangial cells using a common receptor but exhibit different intracellular trafficking patterns. *Lab Invest* 2004; 84:440-451.
36. Teng J, Zhang PL, Russell WJ, Zheng LP, Herrera GA: Insights into mechanisms responsible for mesangial alterations associated with fibrogenic light chains. *Nephron Physiol* 2003; 94:28-38.
37. Tubbs RR, Gephardt GN, McMahon JT, et al. Light chain nephropathy. *Am J Med* Aug 1981; 71:263-269.
38. Weichman K, Dember LM, Prokaeva T et al. Clinical and molecular characteristics of patients with non-amyloid light chain deposition disorders, and outcome following treatment with high-dose melphalan and autologous stem cell transplantation. *Bone Marrow Transplant* 2006; 38:339-343.
39. Zhu L, Herrera GA, Murphy-Ullrich JE et al. Pathogenesis of glomerulosclerosis in light chain deposition disease: Role of transforming growth factor-beta. *Am J Pathol* 1995; 147:375-385.

## **BULLET POINTS**

**Light and heavy chain deposition disease may present with a variety of light microscopic appearances.**

**Pathogenesis of light chain deposition disease is well understood; that is not the case for heavy chain deposition disease.**

**Immunofluorescence stains for light chains are not always positive in light chain deposition disease and establishment of monoclonality may be challenging in some cases.**

**Ultrastructural immunogold labeling may be diagnostic of light / heavy chain deposition disease when other techniques have failed.**

Diagnosis of unusual, early and subtle cases of light/heavy chain deposition diseases requires a high index of suspicion and careful correlation of light, immunofluorescence and ultrastructural findings.

# **Proliferative glomerulonephritis with monoclonal IgG deposits**

**Samih Nasr and Vivette D'Agati**

## **Introduction**

Glomerular diseases caused by monoclonal IgG deposition include light and heavy chain deposition disease (LHCDD) (1), type 1 cryoglobulinemic glomerulonephritis (2), immunotactoid glomerulonephritis (IT) (3), and rarely fibrillary glomerulonephritis (FGN) (3) (Table 1). LHCDD is characterized by the presence of nodular sclerosing glomerulopathy by light microscopy (LM), diffuse, linear staining of glomerular basement membranes (GBM) and tubular basement membranes (TBM) for a single heavy chain and a single light chain by immunofluorescence (IF), and nonfibrillar, “powdery”, continuous electron dense deposits in GBM and TBM by electron microscopy (EM) (1). Type 1 cryoglobulinemic glomerulonephritis exhibits a membranoproliferative or diffuse proliferative glomerulonephritis pattern on LM, usually with prominent intracapillary infiltrating monocytes and distinctive large, glassy intraluminal immune deposits (2). Ultrastructurally, the deposits commonly show an annular-tubular or fibrillar substructure. The glomerular deposits in IT are composed of microtubular structures with a diameter of 30-50 nm and a tendency for parallel alignment, whereas in FGN they are composed of Congo red-negative, randomly-oriented fibrils measuring 16-24 nm in diameter (3).

### **Table 1: Causes of glomerular monoclonal IgG deposition**

- 1- Light and heavy chain deposition disease
- 2- Type 1 cryoglobulinemic glomerulonephritis
- 3- Immunotactoid glomerulonephritis
- 4- Fibrillary glomerulonephritis
- 5- Light and heavy chain amyloidosis

Recently, we and others have encountered patients with a novel form of glomerular injury related to monoclonal IgG deposition that could not be assigned to any of the above conditions, which we termed “proliferative glomerulonephritis with monoclonal IgG deposits” (PGNMID) (4-10). On IF, the glomerular deposits were monoclonal, staining for a single light chain isotype and a single gamma heavy chain subclass. However, LM exhibited endocapillary proliferative or membranoproliferative glomerulonephritis and EM revealed mostly granular electron dense deposits, mimicking ordinary immune-complex glomerulonephritis (4). Here, we present the clinical and pathologic characteristics of 37 patients with PGNMID, representing the largest series to date.

### **Diagnostic criteria for PGNMID**

The following criteria are required for the diagnosis of PGNMID (4):

- 1- Immune deposits staining positive for gamma heavy chain (IgG), with negativity for alpha (IgA) and mu (IgM) heavy chains, indicating restriction to a single immunoglobulin class.
- 2- Positive staining for a single gamma (IgG) subclass (IgG1, IgG2, IgG3, or IgG4).
- 3- Positive staining for a single light chain isotype (kappa or lambda), indicating monoclonality.
- 4- Predominantly granular electron-dense deposits in mesangial, subendothelial, and/or subepithelial locations by EM, resembling immune complex glomerulonephritis.
- 5- Absence of clinical or laboratory evidence of cryoglobulinemia.

### **Clinical features**

The biopsy incidence of PGNMID was 0.17%. The disease was eight-fold rarer than AL amyloidosis and approximately twice as rare as Randall type monoclonal immunoglobulin deposition disease. The mean age at presentation was 54.5 years (range 20-81) and close to 2/3 of patients were >50 years old. There was a female predominance (female-to-male ratio of 2:1). Only 27% of patients had a monoclonal (M)-spike on

standard serum protein electrophoresis (SPEP), urine protein electrophoresis (UPEP), and immunofixation electrophoresis (IFE), whereas multiple myeloma (MM) was rare affecting 3% of patients. None of the patients had lymphadenopathy, hepatosplenomegaly, or lymphoma. One patient had primary renal amyloidosis of the lambda type affecting blood vessels diagnosed concomitantly with PGNMID of the IgG2 lambda type on renal biopsy. Four patients had history of carcinoma. One patient who had detectable IgG $\lambda$  M-spike in serum had an upper respiratory tract infection 5 days prior to presentation with renal failure. Another patient had a history of HIV infection. None of the remaining 35 patients had a history of recent or chronic infection. One patient carried a diagnosis of autoimmune hemolytic anemia. None of the patients had a history of SLE, rheumatoid arthritis, mixed connective tissue disease, or Sjogren's syndrome.

Serum cryoglobulin titers were negative in all patients (performed repeatedly in many patients) and none of the patients had any systemic manifestation of cryoglobulinemia. Hypocomplementemia was present in a quarter of patients (low C3, low C4, or low C3 and C4). Rheumatoid factor, tested in 18 patients, was negative in 17 and positive in 1. Hepatitis C antibody, tested in 30 patients, was negative in 29 and positive in 1 (who had MM and normal serum complements).

At presentation, all patients had proteinuria, which was in the nephrotic range in 69% of patients, and close to a half of patients had full nephrotic syndrome. Microhematuria was documented in 77% of patients, whereas gross hematuria was present in <3% of patients. Two thirds of patients had renal insufficiency, including 3 who were on hemodialysis. The mean serum creatinine was 2.77 mg/dl (range, 0.7-17). Peripheral edema was present in 62% of patients.

### **Pathologic features**

On LM, the glomerular alterations were heterogeneous, with the majority of biopsies displaying variable degrees of endocapillary hypercellularity and duplication of the GBM. The most common pattern of glomerular injury, seen in 57% of cases was membranoproliferative glomerulonephritis characterized by diffuse and global duplication of the GBM with mesangial cell interposition and mesangial expansion by increased mesangial cell number and matrix. Most of these cases also showed

endocapillary hypercellularity and some exhibited segmental membranous features. The second most common pattern, seen in 35% of cases, was endocapillary proliferative glomerulonephritis, characterized by endocapillary hypercellularity and leukocyte infiltration causing luminal occlusion. Some of these cases had associated segmental membranoproliferative features, neutrophil infiltration, or segmental membranous features. The third histological pattern, seen in 5% of cases only, was predominantly membranous glomerulonephritis characterized by GBM thickening and global subepithelial deposits. The fourth and rarest pattern, observed in 3% of cases, was pure mesangial proliferative glomerulonephritis. Crescents were present in 1/3 of cases, affecting a mean of 20% of glomeruli; in 5% of cases crescents involved  $\geq 50\%$  of glomeruli.

By IF, deposits were seen exclusively in the glomeruli, localized mainly to the glomerular capillary wall and mesangium, and generally had a granular texture. IgG was the only immunoglobulin deposited. There was light chain isotype restriction, with sole positivity for kappa in 73% of cases and sole positivity for lambda in 27% of cases. There was glomerular co-deposition of C3 in almost all cases and C1q in 2/3 of cases. Staining for IgG1-4 subclasses showed monotypic deposits, including IgG1 (29% of cases), IgG2 (3% of cases), and IgG3 (68% of cases). No case showed positivity for IgG4.

On EM, the deposits were confined to the glomerular compartment, present primarily in the mesangium and subendothelial space. Subepithelial deposits were less frequent, seen in 57% of patients, and were segmental in most cases.

In 70% of cases, the electron dense deposits had a finely granular texture throughout, without substructure, resembling immune-complex type glomerulonephritis. In the remaining 30% of cases, the deposits were mostly granular, but with focally variegated texture. Rarely, ill-defined fibrils measuring  $<12$  nm in diameter and focal organization into lattice-like arrays with a periodicity of 15 nm were seen involving a portion of otherwise granular deposits.

## **Treatment and outcome**

Most patients were treated with steroids alone or in combination with other immunosuppressive agents, whereas some were treated with renin angiotensin system

blockade alone. Prognosis was variable. Follow-up (mean 30.3 months) was available in 32 patients, of whom 37.5% had complete or partial recovery, 37.5% had persistent renal dysfunction, and 21.9% progressed to ESRD. Five patients (4 with ESRD and 1 with partial recovery) died. None of the patients lacking M-spikes on SPEP/UPEP at presentation subsequently developed M-spike or MM during the follow-up period (up to 114 months), and none of those with M-spikes at presentation subsequently developed MM or lymphoma.

## **Etiology and pathogenesis**

The pathogenesis of PGNMID remains elusive. The absence of underlying infectious, autoimmune, or other systemic disease in the vast majority of patients and the light chain and heavy chain subclass restriction argue against antigen-antibody immune complex deposition and, instead, favor that monoclonal IgG is deposited as a free, noncomplexed immunoglobulin, which has the ability to aggregate to form definable dense deposits. Because up to 2/3 of patients have no detectable M protein (by standard SPEP/UPEP/IFE) even after long follow-up, in these cases we propose that this unique glomerulonephritis may arise in the course of normal immune responses. It is possible that during an immune response (to extrinsic or intrinsic antigens), a clone of B-cells proliferates and produces a monoclonal IgG molecule (particularly IgG3) with ability to self-aggregate and rapidly deposit in glomeruli through entrapment and/or interaction with negatively charged glomerular constituents. The small quantity of this monoclonal IgG may elude detection in by SPEP/UPEP/IFE due to its high avidity for the glomeruli and rapid aggregability favored by its intrinsic physical properties and glomerular sieving itself.

Human IgG is divided into four subclasses that differ in their heavy chain structure, molecular weight, concentration in the serum, isoelectric point (pI), and immunogenicity. Of the 4 subclasses, IgG3, which comprises only 8% of IgG in the circulation, has several properties that allow it to be intrinsically “nephritogenic” (11, 12). (1) It is the most positively charged subclass (pI, 8.2-9.0), favoring affinity for

intrinsic anionic sites in the glomerular capillary wall. (2) It has the highest molecular weight (170.000 Dalton), making it more size-restricted by the glomerular filtration barrier. Thus, in the course of filtration, the intracapillary concentration of circulating IgG3 would be predicted to rise, promoting the potential for intraglomerular aggregation. (3) In fact, IgG3 has the unique physicochemical property of self-aggregability via Fc-Fc interactions and is known to be selectively enriched in murine and human cryoglobulinemia, murine lupus nephritis (13, 14, 2) and human IgG myeloma hyperviscosity syndrome (12). (4) It has the greatest complement fixing capacity, which in turn could activate downstream inflammatory mediators that promote glomerular leukocyte infiltration and proliferation, leading to glomerulonephritis.

These special properties of IgG3 may explain the predominance of this relatively uncommon serum subtype in patients with PGNMID. Monoclonal IgG3 was identified in the glomeruli of two-thirds of patients, particularly those without detectable M-spikes, and was accompanied by co-deposition of C3 in all patients and by hypocomplementemia in one-third of patients. Glomerular C3 activation and resultant hypocomplementemia are also known to occur in other glomerular diseases associated with monoclonal IgG3 deposition such as type 1 cryoglobulinemic glomerulonephritis and IT (2, 3), attesting to its ability to activate complement even in the absence of circulating immune complexes.

In contrast to heavy chain deposition disease in which the CH1 constant domain is deleted, using monoclonal antibodies to epitopes of the constant domains of IgG heavy chains, we found no detectable deletion in any of the constant domains in PGNMID (4). The intact CH2 domain is essential for complement fixation. Amino acid sequencing of glomerular deposits in PGNMID is needed to determine whether there are unique amino acid substitutions in the heavy or light chains that may increase the pI or hydrophobicity of IgG molecules, which could promote the propensity for self-aggregation and glomerular deposition, as has been reported in Randall-type light chain deposition disease (15).

## **Conclusions**

PGNMID is a novel form of glomerulonephritis that mimics immune-complex type glomerulonephritis on LM and EM. However, by IF, the glomerular deposits are monoclonal, staining for a single light chain isotype and a single gamma heavy chain subclass, most commonly IgG3 kappa. Despite the monoclonality, few patients have a detectable serum M-spike, and hematologic malignancy is rare. Furthermore, PGNMID does not appear to represent a premalignant condition. The disease affects adults and is more common in females. Most patients present with nephrotic-range proteinuria and hematuria with or without renal insufficiency. Prognosis is variable, with nearly a quarter of patients progressing to ESRD within 2.5 years despite immunomodulatory therapy.

### References:

1. Lin J, Markowitz GS, Valeri AM, Kambham N, Sherman WH, Appel GB, D'Agati VD: Renal monoclonal immunoglobulin deposition disease: the disease spectrum. *J Am Soc Nephrol.* 12(7):1482-92, 2001
2. Nasr SH, Markowitz GS, Reddy BS, Maesaka J, Swidler MA, D'Agati VD: Dysproteinemia, proteinuria, and glomerulonephritis. *Kidney Int.* 69(4):772-5, 2006
3. Rosenstock JL, Markowitz GS, Valeri AM, Sacchi G, Appel GB, D'Agati VD: Fibrillary and immunotactoid glomerulonephritis: Distinct entities with different clinical and pathologic features. *Kidney Int.* 63(4):1450-61, 2003
4. Nasr SH, Markowitz GS, Stokes MB, Seshan SV, Valderrama E, Appel GB, Aucouturier P, D'Agati VD: Proliferative glomerulonephritis with monoclonal IgG deposits: a distinct entity mimicking immune-complex glomerulonephritis. *Kidney Int.* 65(1):85-96, 2004
5. Alpers CE, Tu WH, Hopper J Jr, Biava CG: Single light chain subclass (kappa chain) immunoglobulin deposition in glomerulonephritis. *Hum Pathol.* 16(3):294-304, 1985
6. Evans DJ, Macanovic M, Dunn MJ, Pusey CD: Membranous glomerulonephritis associated with follicular B-cell lymphoma and subepithelial deposition of IgG1-kappa paraprotein. *Nephron Clin Pract.* 93(3):c112-8, 2003

7. Lee JG, Moon KC, Lee JE, Kim P, Lee JG, Kim JH, Lee KY: A Case of Proliferative Glomerulonephritis with Monoclonal IgG Deposits. *Korean J Nephrol.* 23(6):987-991, 2004
8. Komatsuda A, Masai R, Ohtani H, Togashi M, Maki N, Sawada K, Wakui H: Monoclonal immunoglobulin deposition disease associated with membranous features. *Nephrol Dial Transplant.* 23(12):3888-94, 2008
9. Bridoux F, Zanetta G, Mougnot B, Goujon JM, Vanhille P, Bauwens M, Chevet D, Ronco P, Preud'homme JL, Touchard G: Glomerulopathy with non-organized and non-Randall type monoclonal immunoglobulin deposits: a rare entity. [Abstract]. *J Am Soc Nephrol* 12:94A, 2001
10. Geldenhuys L and Jones B: Glomerulonephritis with monoclonal immunoglobulin deposits [Abstract]. *J Am Soc Nephrol* 19:671A, 2008
11. Grey HM, Hirst JW, Cohn M: A new mouse immunoglobulin: IgG3. *J Exp Med.* 1;133(2):289-304, 1971
12. Capra JD, Kunkel HG: Aggregation of gamma-G3 proteins: relevance to the hyperviscosity syndrome. *J Clin Invest.* 49(3):610-21, 1970
13. Abdelmoula M, Spertini F, Shibata T, Gytoku Y, Luzuy S, Lambert PH, Izui S: IgG3 is the major source of cryoglobulins in mice. *J Immunol.* 15;143(2):526-32, 1989
14. Alpers CE, Smith KD: Cryoglobulinemia and renal disease. *Curr Opin Nephrol Hypertens.* 17(3):243-9, 2008
15. Vidal R, Goñi F, Stevens F, Aucouturier P, Kumar A, Frangione B, Ghiso J, Gallo G: Somatic mutations of the L12a gene in V-kappa (1) light chain deposition disease: potential effects on aberrant protein conformation and deposition. *Am J Pathol.* 155(6):2009-17, 1999

## **PGNMID: Brief bullet points (Renal #3 – Nasr)**

- 1- PGNMID is a novel form of glomerular injury related to monoclonal IgG deposition, most commonly IgG3κ
- 2- It affects adults and is more common in females. Only a quarter of patients have detectable M spike and hematologic malignancy is rare. Renal presentation includes nephrotic-range proteinuria and hematuria with or without renal insufficiency.
- 3- On IF, the glomerular deposits are monoclonal, staining for a single light chain isotype and a single gamma heavy chain subclass. However, LM exhibits endocapillary proliferative or membranoproliferative GN and EM reveals mostly granular electron dense deposits, mimicking ordinary immune-complex GN
- 4- Prognosis is variable with close to a fourth of patients progressing to ESRD.
- 5- Pathogenesis remains elusive. Deposition of monoclonal IgG as a free, noncomplexed immunoglobulin, which has the ability to aggregate to form definable dense deposits is favored.

## **Key words Renal #2 - Nasr**

PGNMID

Proliferative glomerulonephritis

Membranoproliferative glomerulonephritis

Monoclonal IgG deposits

IgG3

# Molecular Diagnosis of Amyloidosis

*Alan Solomon, MD*

The amyloidoses represent a group of acquired or inherited disorders characterized by the pathologic deposition of wild-type or mutated proteins as fibrils within the kidney or other vital organs/tissues throughout the body. Since at least 25 biochemically distinct amyloidogenic molecules have been identified, of which 9 are known to form renal amyloid deposits (Table 1), it is essential for therapeutic and prognostic purposes that the kind of amyloid be correctly established. Heretofore, the diagnosis has been dependent principally upon immunohistochemistry (and ancillary clinical data); however, limitations in antibody reactivity and specificity have resulted in misinterpretation, particularly when differentiating primary or light chain-associated (AL) from secondary or serum amyloid A protein-associated (AA) amyloidosis.

To ascertain if an individual has AL, AA, or some other kind of amyloid disease, the green birefringent material contained in biopsy-derived specimens should be extracted and analyzed chemically. In this regard, we have utilized tandem mass spectrometry (MS/MS) to gain this information using sections cut from formalin-fixed, paraffin-embedded tissue biopsies or subcutaneous fat aspirates scraped from glass microscopic slides (Figure 1).

Given the fact that the clinical management and ultimate fate of patients with amyloidosis is dependent on the amyloid type (Table 2), it is crucial that the nature of the fibrillar protein be established unequivocally in order to avoid inappropriate and costly therapy that can have dire and possible legal consequences.

## References

Murphy CL, Eulitz M, Hrcic R, Sletten K, Westermark P, Williams T, Macy SD, Wooliver C, Wall J, Weiss DT, and Solomon A. Chemical typing of amyloid protein contained in formalin-fixed paraffin-embedded biopsy specimens. *Am. J. Clin. Pathol.* **116**, 135-142, 2001.

Solomon A, Weiss DT, and Herrera GA. Renal diseases associated with multiple myeloma and related plasma cell dyscrasias. *In* Biology and Management of Multiple Myeloma. Berenson, J.R. Ed. Humana Press, New Jersey, 2004; pp. 281-302.

Murphy CL, Wang S, Williams T, Weiss DT, and Solomon A. Characterization of systemic amyloid deposits by mass spectrometry. *Methods Enzymol.* **412**,48-62, 2006.

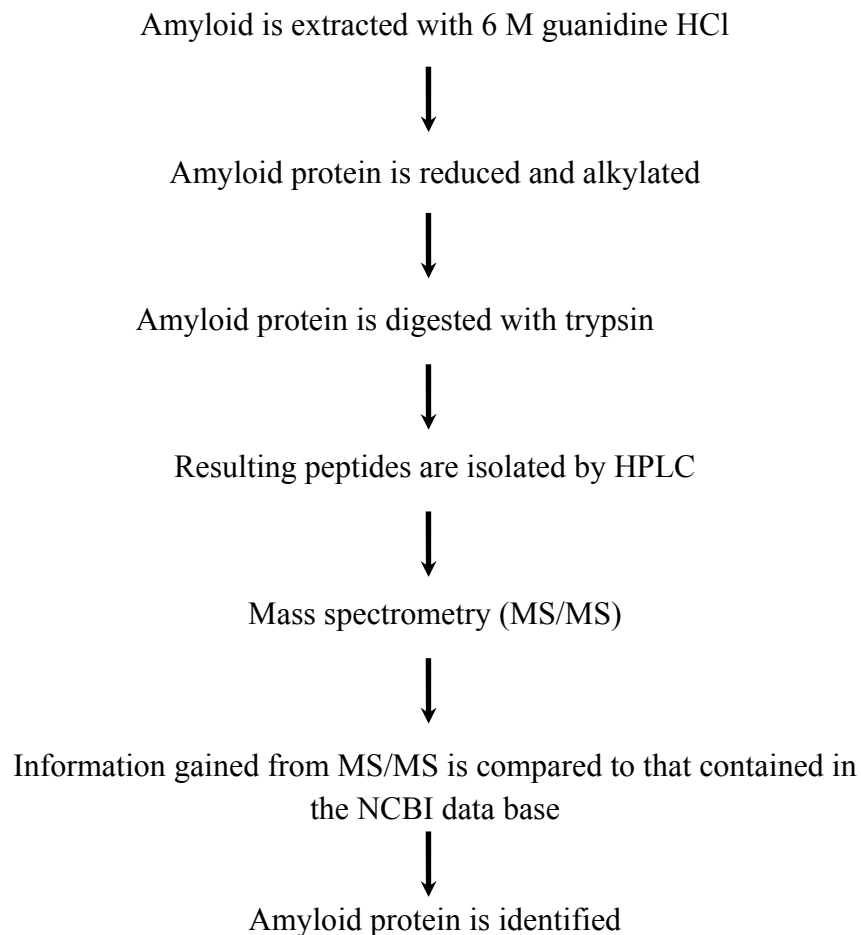
**Table 1: Renal Amyloidoses**

Precursor Protein	Wild-Type (WT) / Mutated (MUT)	Type of Amyloid
Light Chain ( $\kappa$ or $\lambda$ )	WT	AL
Serum Amyloid A 1/2 (SAA1/2)	WT	AA
Serum Amyloid A 4 (SAA4)	MUT	AA
Apolipoprotein A-I (Apo A-I)	MUT	AApo A-I
Apolipoprotein A-II (Apo A-II)	MUT	AApo A-II
Fibrinogen (FIB)	MUT	AFIB
Lysozyme (LYS)	MUT	ALYS
Transthyretin (TTR)	MUT	ATTR
Leucocyte Cell-Derived Chemotaxin 2 (LECT 2)	WT	ALECT 2

**Table 2: Treatment of Amyloidosis**

Amyloid Type	Therapy
AL	Anti-plasma cell chemotherapy (high or conventional dose)
AA	Anti-inflammatory therapy
AAPO A-I AAPO A-II AFIB ALYS ATTR ALECT 2	Liver/Kidney transplantation

**Figure 1: Flowchart - Chemical Analyses of Amyloid Extracted from Formalin-Fixed, Paraffin-Embedded Sections or Fat Aspirates**



**Bullet Points:**

- **Identification of amyloid type by immunohistochemistry may be inconclusive or inaccurate**
- **Definitive identification of amyloid requires chemical analysis of the green birefringent material**

**Key Words:**

**amyloidosis, amyloid type, renal amyloidosis, chemical typing**

# **CYOGLOBULINEMIA RELATED RENAL/GLOMERULAR CHANGES**

**FRANCO FERRARIO  
RENAL IMMUNOPATHOLOGY CENTER  
SAN CARLO BORROMEO HOSPITAL  
MILAN\_ITALY**

**KEY WORDS: Mixed Cryoglobulinemia/type II Cryoglobulins/HCV  
infection/hypocomplementemia/mesangial proliferative  
glomerulonephritis/membranoproliferative glomerulonephritis.**

## **Introduction**

Mixed cryoglobulins (MC) are plasma proteins that precipitate reversibly at low temperatures and are composed of immunoglobulins including one with rheumatoid activity. Two types of MCs can be defined on the basis of Brouet's classification (1). Type II cryoglobulins consist of one monoclonal immunoglobulin (usually IgMk) having rheumatoid activity against a polyclonal IgG while type III cryoglobulins are characterised by a combination of polyclonal immunoglobulins. Most MCs, defined as "secondary mixed cryoglobulins", have been detected in patients with connective tissue disorders, lymphoproliferative disorders, chronic infections, non-infectious hepatobiliary diseases or immunologically mediated glomerular diseases. In approximately 30% of cases, no underlying disease was present, and cryoglobulinaemia was defined as essential. The clinical syndrome of essential mixed cryoglobulinaemia was first described by Meltzer et al. in 1966 (2). It was characterised by purpura, weakness, arthralgia as well as by glomerular lesions in some patients. Several subsequent reports further defined this syndrome, indicating that its incidence varies in different geographical areas, with the majority of cases having been reported in the Mediterranean countries, namely Italy, France, Spain and Israel (3,4).

An important step forward in the knowledge of this disease was achieved when HCV infection was found in the majority of patients with "essential" mixed cryoglobulinaemia of either type (5,6,7,8,9,10,11), suggesting that these cases should no longer be considered "essential".

The clinical symptoms range from mild palpable purpura, arthralgias and fatigue, to severe vasculitis with skin necrosis, glomerulonephritis, involvement of peripheral nerves, central nervous system, gastrointestinal tract, lungs, myocardium (12,13,14,15,16).

In rheumatologic surveys, type III MC patients out-numbered those with type II MCs (2,12). On the contrary, surveys based on renal involvement indicated a large prevalence of type II MCs, with IgMk usually being the monoclonal IgM (17,18).

I would like to present a large multicentre , retrospective study, of the Italian Group of Renal Immunopathology that collected the clinical and serological data of 146 cases of biopsy-proven cryoglobulinaemic glomerulonephritis recorded in the Italian Registry of Renal Biopsies in 1995

### **Histological analysis**

Histological specimens were available for all 146 patients and were representative enough to characterise the patterns of glomerular involvement. The histological material was independently examined by 2 investigators. Immunofluorescence results were available for all patients. A mean of  $17 \pm 11.2$  glomeruli (average 5-70) were observed by means of light microscopy. Cases with advanced sclerosis were excluded from the study (90% showed less than 20% glomerular hyalinosis). Enough histological material was available for the quantitative and semi-quantitative evaluation of 130 out of 145 cases. This included the following features: 1) percentage of global glomerular sclerosis, segmental glomerular sclerosis, extracapillary proliferation 2) amount of mesangial sclerosis (grade 0 to 3), mesangial proliferation (0-3), endocapillary proliferation and/or exudation (0-3), diffuse thickening of the capillary wall (0-3), double contours (0-3), endoluminal hyaline thrombi and tubular atrophy (1:<30%; 2:>30<60%; 3:>60% of glomeruli or cortex), interstitial infiltrates (0-3 as per tubular atrophy), interstitial fibrosis (0-3 as per tubular atrophy) , and the presence or absence of: arteriolar hyalinosis, intimal fibrosis, miointimal hyperplasia, arteritis, thrombotic microangiopathy.

On the basis of the above described features, arbitrary chronic and activity histologic indexes were calculated for each case.

### **Morphologic analysis of kidney biopsy and the clinical-pathological correlations.**

Morphologic analysis identified the following histological patterns :

- 1) Membranous nephropathy (2 cases): characterised by the same morphology as the primary form. Prevalent sub-epithelial deposits of IgM, IgG and C3 , but with no proliferative lesions. Electron microscopy examination was available for one of the 2 cases , but showed no crystalloid structured deposits.
- 2) Mesangial proliferative glomerulonephritis (10 cases, group A): characterised by mesangial expansion and proliferation, without exudation or endocapillary proliferation. Isolated proteic endoluminal thrombi were only found in few cases. Immunofluorescence examination showed segmental and irregular deposits of IgM, IgG and C3 in mesangial and paramesangial localisations and within very few endocapillary thrombi.
- 3) Focal membranoproliferative glomerulonephritis (10 cases, group B): having a typical immunohistological pattern of cryoglobulinaemic glomerulonephritis, but involving < 50% of the glomeruli.
- 4) Diffuse membranoproliferative GN (108 cases, group C): having the same lesions as group 2, but involving more than 50% of the glomeruli. Four cases of

membranoproliferative GN showed in addition to the common IF pattern the presence of IgA deposits with prevalent mesangial but also parietal localization.

The main clinical features of the 3 histological groups (A, B and C) are shown in Table III

Table III: Clinical features at biopsy. Results are expressed as percentages unless indicated otherwise

histologic groups (# patients)	Mesangial proliferative "A" (10)	Focal membranoproliferative "B" (10)	Diffuse membranoproliferative "C" (108)
Age (mean $\pm$ s.d.)	51.5 $\pm$ 13.3	55.4 $\pm$ 9.7	57.9 $\pm$ 10.53
M/F	60/40	40/60	43/57
Time from onset of nephropathy (mean $\pm$ s.d.)	13 $\pm$ 21.2	28.4 $\pm$ 37.14	18 $\pm$ 24.6
Serum Creatinine (mg/dL) (mean $\pm$ s.d.)	1.3 $\pm$ 0.7	2.5 $\pm$ 2.2	2.6 $\pm$ 1.8
Serum creatinine >1.5 mg	40	30	33
Proteinuria (g/24h) (mean $\pm$ s.d.)	2.5 $\pm$ 3.0	2.9 $\pm$ 2.9	4.0 $\pm$ 9.7
Hematuria	100	100	100
Hypertension	60	40	66.7
$\downarrow$ C3	20	30	52
$\downarrow$ C4	60	60	93
$\uparrow$ ALT	30	30	22
Nephrotic Syndrome	30	30	41.5
Acute Nephritic Syndrome	-	-	7.5
Orinary Abnormalities	50	60	42.5
Chronic renal insufficiency	20	-	7.5
Acute renal failure	-	10	1

Serum creatinine levels were lower in group A than in the others groups, even though the percentage of patients with renal failure was substantially the same. Patients in group 3 showed higher levels of proteinuria, a higher incidence of nephrotic syndrome, and lower C4 levels.

Extrarenal symptoms and signs were more frequently observed in patients with a membranoproliferative pattern, while on the contrary, only 40% of patients with mesangioproliferative GN had extrarenal symptoms and signs.

The characterisation of cryoprecipitate was available in 117 cases. IgM-IgG was the component in 116 cases, while it was IgG-IgA in 1 case. Type III cryoglobulin was more frequent in group A (55%) than it was in groups B (33%) or C (20%). A monoclonal IgM $\kappa$  was present in 44%, 66%, and 77% of cases, respectively, in groups A, B, and C. An IgM $\lambda$  component was only found in 3 Group C cases.

The main lesions in Group A included global and diffuse, slight mesangial matrix expansion and mesangial cell proliferation. Focal endoluminal thrombi were found in very few cases. Proliferation, exudation, and thickening of the capillary wall in the Group B patients were mild and irregularly distributed within the same glomerulus and among glomeruli. Endoluminal thrombi were only found in 1 out of 10 cases. The proliferative and exudative abnormalities we observed in Group C were usually severe, with segmental distribution in 15% of cases. Centriolobular sclerosis was present in 50% of cases. The capillary wall abnormalities were not correlated to proliferative lesions. Double contour appearance of the capillary wall was present in 70% of cases, and endoluminal thrombi were found in more than 50%. Extracapillary proliferation was present in 16% of cases. Interstitial leukocyte infiltration, which was usually focal, was more often present in the membranoproliferative forms (60% in Groups B and C), and was correlated to the intensity of the proliferative glomerular lesions. Interstitial fibrosis, which was usually focal, was still present in the membranoproliferative forms: 90% in Group B and 70% in Group C, but only 50% in Group A. Arteriosclerotic lesions were present in 30% of cases, and no differences were observed among groups. Arteritis was rare (5.5%).

No differences were found with regards to the chronicity index among the 3 histological groups we took into consideration. It was, respectively, : Group A -  $4.3 \pm 2.8$ , Group B -  $4.1 \pm 1.9$ , and Group C -  $4.0 \pm 2.3$ . On the contrary, the activity index increased as the number of proliferative and inflammatory lesions grew and was, respectively, : group A -  $3.6 \pm 2.3$ , group B -  $4.8 \pm 2.5$ , and group C -  $8.4 \pm 9.0$ .

## References

1. Brouet JC, Clauvel JP, Danon F, Klein M, Seligmann M. Biological and clinical significance of cryoglobulins. A report of 86 cases. *Am J Med* 1974; 57: 775-78.
2. Meltzer M, Elias K, McCluskey RT, Cooper N, Franklin EC. Cryoglobulinemia, a clinical and laboratory study. *Am J Med* 1966; 40: 837-56.
3. Gorevic PD. Mixed cryoglobulinemia: an update of recent clinical experience. In *Antiglobulins, cryoglobulins and glomerulonephritis*, edited by Ponticelli C, Minetti L, D'Amico G, Dordrecht, Boston, Lancaster, Martinus Nijhoff Publishers 1986, 179-92.
4. **D'Amico G, Colasanti G, Ferrario F, Sinico RA: Renal involvement in essential mixed cryoglobulinemia. *Kidney Int* 35; 1004-1014: 1989.**
5. Pascual M, Perrin L, Giostra E, Schifferli JA. Hepatitis C virus in patients with cryoglobulinemia type II. *Infectious Dis* 1990; 162: 569-75.
6. Durand JM, Lefevre P, Harle JR, Bonnat J, Vitviski L, Soubeyrand J. Cutaneous vasculitis and cryoglobulinemia type II associated with hepatitis C virus infection. *Lancet* 1991; 337: 499-500.
7. Casato M, Taliani G, Pucillo LP, Goffredo F, Lagana B, Bonomo L. Cryoglobulinemia and hepatitis C virus. *Lancet* 1991; 337: 449-53.
8. Misiani R, Bellavita P, Fenili D, Borelli G, Marchesi D, Massazza M, Vendramin G, Comotti B, Tanzi E, Scudeller G, Zanetti A. Hepatitis C virus infection in patients with essential mixed cryoglobulinemia. *Ann Intern Med* 117: 573-77, 1992.
9. Ferri C, Longombardo G, La Civita L, Bombardieri S, Greco F, Highfield P, Corbishley T. Hepatitis C virus, autoimmune liver disease and cryoglobulinaemic hepatitis. *J Hepatol.* 1992;16:242-3.
10. Agnello V, Chung RT, Kaplan LM. A role for hepatitis C virus infection in type II cryoglobulinemia. *N Engl J Med* 1992;327: 1490-5.
11. Ferri C, Monti M, La Civita L, Longombardo G, Greco F, Pasero G, Gentilini P, Bombardieri S, Zignego AL. Infection of peripheral blood mononuclear cells by hepatitis C virus in mixed cryoglobulinemia. *Blood.* 1993 15;82:3701-4.
12. Invernizzi F, Pioltelli P, Cattaneo R, Gavazzeni V, Borzini P, Monti G, Zanussi C. A long-term follow-up study in essential cryoglobulinemia. *Acta Haematol.* 1979;61:93-9.
13. Gorevic PD, Kassab HJ, Levo Y, Kohn R, Meltzer M, Prose P, Franklin EC. Mixed cryoglobulinemia: clinical aspects and long-term follow-up of 40 patients. *Am J Med.* 1980;69:287-308.
14. Tarantino A, De Vecchi A, Montagnino G, Imbasciati E, Mihatsch MJ, Zollinger HU, Di Belgiojoso GB, Busnach G, Ponticelli C. Renal disease in essential mixed cryoglobulinemia. Long term follow-up of 44 patients. *Q J Med* 1981; 50:1-30.
15. Monti G, Galli M, Invernizzi F, Pioltelli P, Saccardo F, Monteverde A, Pietrogrande M, Renoldi P, Bombardieri S, Bordin G. Cryoglobulinaemias: a

- multi-centre study of the early clinical and laboratory manifestations of primary and secondary disease. GISC. Italian Group for the Study of Cryoglobulinaemias. QJM 1995;88:115-26.
16. Rieu V, Cohen P, André MH, Mouthon L, Godmer P, Jarousse B, Lhote F, Ferriere F, Deny P, Buchet P, Guillevin L. Characteristics and outcome of 49 patients. Rheumatology 2002; 41:290-300.
  17. Tarantino A, Campise M, Banfi G, Confalonieri R, Bucci A, Montoli A, Colasanti G, Damilano I, D'Amico G, Minetti L. Long-term predictors of survival in essential mixed cryoglobulinemic glomerulonephritis. Kidney Int 1995; 47: 618-23.
  18. Barbiano di Belgiojoso G, Montoli A, Tarantino A, *et al.* clinical and histological correlations in essential mixed cryoglobulinemia glomerulonephritis. In: Antiglobulins, Cryoglobulins and Glomerulonephritis, edited by Ponticelli C, Minetti L, D'Amico G, Dordrecht, Boston, Lancaster, martinus Nijhoff Publishers 1986, 203-10.

## BULLET POINTS:

Mixed cryoglobulins are plasma proteins that precipitate reversibly at low temperatures.

Type II cryoglobulins consist of one monoclonal immunoglobulin (usually IgM kappa) having rheumatoid activity against a polyclonal IgG.

HCV infection is found in the majority of patients with “essential” mixed cryoglobulinemia suggesting that these cases should no longer be considered “essential”.

Cryoglobulinemic glomerulonephritis may present a variety of light microscopy appearances.

The most common morphological pattern is a membranoproliferative exudative glomerulonephritis with frequent presence of intraluminal thrombi.

By immunofluorescence the deposits are positive for IgM, IgG and C3 (cryoimmunoglobulins).